

available at [www.sciencedirect.com](http://www.sciencedirect.com)journal homepage: [www.eu-openscience.europeanurology.com](http://www.eu-openscience.europeanurology.com)

European Association of Urology

## Nightmares in Urology: Open Science

# Red Out: Bleeding During Robotic Retroperitoneal Lymph Node Dissection and Strategies To Manage It

Fairleigh Reeves<sup>\*</sup>, Natalie George, Ben Challacombe

The Urology Centre, Guy's and St. Thomas' NHS Foundation Trust, London, UK

### Article info

#### Article history:

Accepted September 8, 2022

#### Associate Editor:

M. Carmen Mir

#### Keywords:

Testis cancer  
Retroperitoneal lymph node dissection  
Robotic  
Bleeding  
Surgical technique

### Abstract

Robotic retroperitoneal lymph node dissection is emerging as an attractive minimally invasive technique to remove residual and recurrent retroperitoneal masses in patients with germ cell malignancies. It has huge potential benefits for patients in terms of lower rates of blood loss, ileus, postoperative pain, and scarring, and faster return to full activity. Inadvertent injury to the great vessels, lumbar tributaries, and other vessels is not uncommon and requires a calm but strategic management response. A thorough knowledge of the standard anatomy, specific pathology, and anatomic variations will help robotic surgeons in managing intraoperative haemorrhage. We describe the anatomy of the retroperitoneal vessels, surgical case selection, and the technical and nontechnical skills essential for success in this complex and high-risk procedure.

**Patient summary:** Robot-assisted surgical removal of lymph nodes from the area behind the abdominal cavity is a complex operation that has minimal bleeding if all goes well. However, as it involves operating on the major abdominal blood vessels, there is a risk of life-threatening bleeding that the operating team must be able to rapidly control. Effective teamwork and a range of advanced technical skills are required to respond to any serious bleeding.

© 2022 The Author(s). Published by Elsevier B.V. on behalf of European Association of Urology. This is an open access article under the CC BY-NC-ND license (<http://creativecommons.org/licenses/by-nc-nd/4.0/>).

## 1. Introduction

Many robotic surgeons have understandably been cautious in adopting robotic retroperitoneal lymph node dissection (rRPLND), as it is a technically challenging procedure with potential for significant complications. Although the majority of published series have reported limited blood loss [1,2], owing to the nature of the surgery, there is a need

to be aware that significant bleeding can occur. This arises mostly from lumbar veins or the great vessels.

rRPLND is not a procedure for novice surgeons. The American Urological Association guidelines recommend offering minimally invasive RPLND only when the surgeon has appropriate expertise, and acknowledge that long-term data on oncological outcomes are lacking [3]. Similarly, a cautionary report of adverse oncological outcomes

<sup>\*</sup> Corresponding author. The Urology Centre, Guy's and St. Thomas' NHS Foundation Trust, London, UK.

E-mail address: [fairleighr@gmail.com](mailto:fairleighr@gmail.com) (F. Reeves).



following these procedures has been published [4]. As rRPLND practice expands, we must remain vigilant in reporting and assessing outcomes to ensure excellent oncological results and freedom from complications. Here, we concentrate on prevention and control of bleeding.

rRPLND surgeons must have a range of techniques to overcome bleeding in what is often a high-pressure situation. Historically, the natural progression was for experienced open surgeons to transition to rRPLND, but we are now in an era in which established robotic surgeons are expanding their repertoire to include RPLND without necessarily having a strong grounding in previous open surgery for this procedure. Our aim in this article is to provide practical considerations for surgeons as they expand their practice.

## 2. Methods

A 26-yr-old man presented with a right testicular mass. Tumour markers revealed  $\beta$ HCG of 7500 and AFP of 530. Ultrasound confirmed a hypoechoic 6-cm testis tumour. Contrast computed tomography (CT) staging showed a 5-cm right paracaval and interaortocaval mass. There were no other sites of disease. The patient was treated with primary chemotherapy using three cycles of bleomycin, etoposide, and platinum. A subsequent follow-up scan at 6 mo revealed a residual 3-cm paracaval mass of a cystic nature suggestive of teratoma differentiated. He underwent supine RPLND using a five-port technique in a steep Trendelenberg position.

## 3. Complication events and management

During the paracaval dissection, it was found that the mass was closely adherent to the inferior vena cava (IVC) and a lumbar vein was inadvertently avulsed. At this time, 3 h into the procedure, the surgeon calmly but clearly alerted the team to the issue so that the preprepared rescue suture was at hand and the anaesthetic team was aware of the potential need for resuscitation and blood. Pneumoperitoneum was quickly increased to 20 mm Hg and pressure was applied to the bleeding site using the assistant suction device. A tonsil swab was also introduced to allow application of broader pressure. Using a 4-0 PROLENE suture, the bleeding vein was oversewn with a number of throws until haemostasis was achieved.

## 4. Discussion

There is no doubt that the operating room is a high-risk area. In one study, nearly 50% of all adverse events among hospitalised patients were associated with a surgical operation [5]. In other series, just over half of the surgical adverse events described were avoidable [6].

The key to limiting the risk of catastrophic bleeding during rRPLND is appropriate preoperative preparation and attention to technical and nontechnical intraoperative factors (Table 3). Anticipation of potential problems will

increase the chance of avoiding haemorrhage and facilitate efficient control should it occur.

### 4.1. Preoperative preparation

To set up for success, knowledge of the relevant vascular anatomy (including potential anomalies), careful case selection, and appropriate surgical experience are essential.

A prerequisite for all surgeons is a thorough knowledge of the anticipated normal anatomy, as well as potential vascular anomalies. The templates for dissection have been well covered by other authors [1,7]. Here we concentrate on the relevant vascular anatomy (Fig. 1).

Lumbar veins are often unpaired and tend to be inconsistent [8,9]. During paracaval dissection, with the IVC rolled medially, two or three lumbar veins are usually encountered, the largest of which tends to be the most superior, found near the right renocaval junction [9].

In interaortocaval dissection, the left lumbar veins usually drain between the upper and lower right lumbar veins. According to one cadaveric study, the presence of two veins was most frequent, with a larger common lumbar trunk (receiving multiple left-sided tributaries) found at roughly the same level as the inferior mesenteric artery (IMA) [9]. However, in another study there were more veins noted on the left than on the right [8], further highlighting their variability. On the left, a lumbar vein may also drain into the left renal vein, although in one study this only occurred in 43% of patients [8].

In contrast to the variability of lumbar veins, lumbar arteries tend to be spaced equally and develop in pairs, with the second to fourth arteries found beneath the level of the renal vein. This predictability means that knowing the position of the right lumbar arteries can facilitate location of their left-sided pairs during para-aortic dissection [9]. In a small number of cases a lumbar artery may begin as a common trunk that subsequently branches to both sides [8]. During cranial dissection, care is needed to avoid confusing an accessory lower-pole renal artery, which up to 20% patients may have, with a lumbar vessel [7].

During preaortic dissection, it is our preference to preserve the IMA if possible. However, the IMA can usually be safely sacrificed if adequate supply to the colon is maintained by the marginal artery.

When establishing an rRPLND practice, it is important that cases are carefully selected. Lesion size is the first criterion to consider. Masses of 1–5 cm are advisable for selection, as the degree of difficulty will be greater for larger masses. The relationship between the mass and the vessels within the surgical field will also understandably influence the risk of bleeding. In general, masses with <50% effacement (direct vessel contact) are preferred. The surgeon should anticipate that masses with >50% effacement may be significantly adherent, and dissection should proceed with caution. How well defined the border/edge of the mass is on CT is also a predictor of ease of dissection, with poorly defined masses often representing necrosis or seminoma. It is important to also consider areas of known vascular concern (Table 1). Our experience is that the risk of bleeding is significantly higher if the mass is in one of these areas.

**Table 1 – Anatomic areas with a higher risk of bleeding risk**

Area	Considerations
Posterior branch of the left lumbar renal vein	Mobilise the lymph node packet fully before clipping the superior aspect so that the lumbar vein can be identified and avoided.
Posterior to the inferior vena cava	Beware of short lumbar veins running posteriorly. Gain exposure superiorly and inferiorly to allow clip ligation.
Inter-aortocaval superior border	Identify the right renal artery before clipping the lymph node packet to avoid damage or partial ligation.
Inferior mesenteric artery (IMA)	If sparing the IMA, ensure there is adequate exposure to reduce risk of avulsion of the IMA or other small arteries while mobilising the lymphatics.

**Table 2 – Equipment that should be available for robotic retroperitoneal lymph node dissection (not all the equipment has to be opened)**

Surgical instruments	
Robotic instruments	Fenestrated bipolar forceps Prograsp Monopolar scissors Robotic Hem-o-Lok applier Robotic vessel sealer
Bedside assistant laparoscopic instruments	Atraumatic grasper Suction Laparoscopic Hem-o-Lok applier (purple/gold/green) Pneumatic clip applier (Challenger 5 mm) Scissors
Clamps	Laparoscopic Satinsky clamp Robotic bulldog clamps
Open set	Retractor Major vascular tray
Sutures	
2-0 PROLENE ×2	Bowel retraction 25 cm with clip and a 2-cm tail (used for initial exposure in the supine approach)
4-0 PROLENE	Rescue stitch, 12 cm with clip and 12 cm without clip (for most vascular bleeding)
5-0 PROLENE	Rescue stitch, 12 cm with clip and 12 cm without clip (for inferior vena cava bleeding)

Postchemotherapy cases can also be challenging, as these patients tend to have a higher degree of fibrosis, which leads to adhesion to great vessels [1,10] and higher average blood loss [2]. In our institution we have performed more than 20 postchemotherapy rRPLND procedures without major complications [11]. However, if considerable desmoplastic reaction is predicted, the open approach may be preferable.

Although a history of previous surgery may result in adhesions that make access challenging and may increase risk of vascular injury, rRPLND for in-field recurrence after

previous open RPLND has been successfully performed in selected cases in our institution. Obesity is another patient factor that can impose additional intraoperative challenges. However, depending on the fat distribution, a minimally invasive approach may facilitate access, as adequate exposure in patients with significantly elevated body mass index can be challenging even in open surgery.

In preparation for surgery, it is imperative to study the most up-to-date scans in detail, evaluating the mass location and its relationship to the vasculature, including any anatomic anomalies. When defining the field of dissection, prechemotherapy scans must also be reviewed to ensure that all nodal tissue from areas initially involved by the disease are cleared.

Owing to the breadth of skills required, robotic surgeons who are contemplating introducing this procedure into their practice should master other core robotic procedures first to ensure they have a versatile set of skills on which to build. In particular, experience in complex partial nephrectomy, nephroureterectomy + lymphadenectomy, and advanced nephrectomy with caval involvement provide valuable skills in dissection, vessel isolation, and suturing that can assist in stepwise progression towards rRPLND. Similarly, an experienced team is required. Perhaps most important is the expertise of the bedside assistant, but proficient and calm anaesthetic and nursing support is also vital. In the event of major bleeding, the entire team must be capable of responding swiftly and effectively to assist the surgeon in safely gaining control.

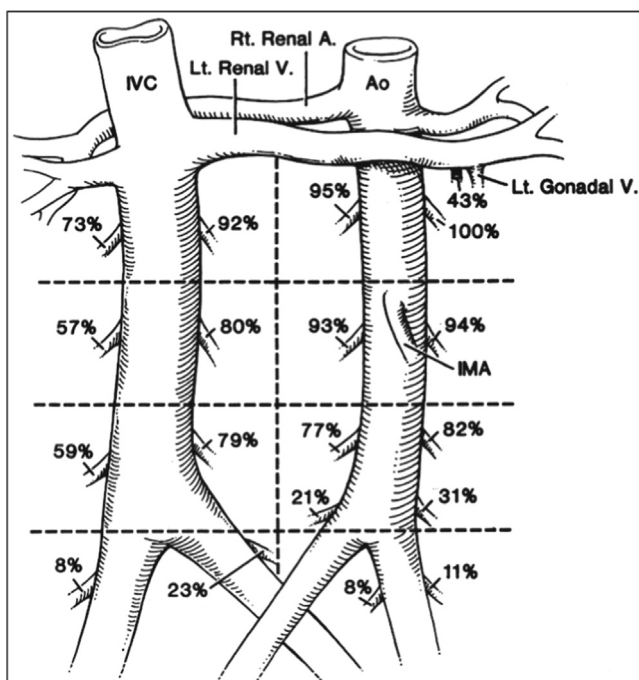
#### 4.2. Intraoperative considerations

Intraoperative success relies on both technical and nontechnical factors.

**Table 3 – Key tips**

<b>Careful case selection</b>	<ul style="list-style-type: none"> <li>– Mass size 1–5 cm</li> <li>– &lt;50% effacement of the great vessels</li> <li>– Use caution for fibrotic reactions in postchemotherapy cases</li> </ul>
<b>Team briefing</b> (in addition to the WHO checklist)	<ul style="list-style-type: none"> <li>– Discuss the anticipated case difficulty and specific areas of concern to ensure that all team members are prepared</li> <li>– Ensure that the team is able and the equipment available for emergency undocking and open conversion if needed</li> <li>– Ensure that blood products are available</li> <li>– Ensure there is adequate gas for uninterrupted pneumoperitoneum</li> <li>– Ensure that rescue sutures are prepared and all the equipment is functioning</li> </ul>
<b>Control of venous bleeding</b>	<ul style="list-style-type: none"> <li>– Increase pneumoperitoneum</li> <li>– Control by either grasping the bleeding point with a robotic instrument if possible without causing further trauma, or apply direct pressure with a robotic or assistant instrument (±gauze)</li> <li>– If suitable, apply clips (may need to oversee to ensure they are secure)</li> <li>– If not suitable for clips, use rescue sutures with or without clips</li> </ul>
<b>Control of arterial bleeding</b>	<ul style="list-style-type: none"> <li>– Control will depend on the size of the vessel (diathermy/clip/suture)</li> <li>– Conversion may be required for aortic injury if not amenable to robotic repair</li> </ul>

WHO = World Health Organization.



**Fig. 1** – Anatomic distribution of the lumbar arteries (A.) and veins (V.) in the retroperitoneum. Numbers denote the frequency of finding a certain branch among 102 consecutive retroperitoneal lymph node dissections [6]. IVC = inferior vena cava; Ao = aorta; Lt. = left; Rt. = right; IMA = inferior mesenteric artery. Reprinted from Baniel et al [8].

#### 4.2.1. Technical skills

Robotic surgery offers various advantages to the open approach. Overall blood loss is low, with most rRPLND series reporting average blood loss of <100 ml [1,2]. Although a difference in case selection for the two techniques will have an impact on this finding, there are several factors that make robotic surgery favourable with respect to bleeding risk. The effect of pneumoperitoneum in robotic surgery provides effective tamponade for venous bleeding. We use an AirSeal system for our assistant port in all robotic cases. The valveless trocar design has unique pressure-sensing capabilities that facilitate stable pneumoperitoneum, as well as automatic smoke evacuation, which enhances vision. Pneumoperitoneum, in combination with endoscope magnification, provides optimal vision to facilitate fine dissection. Suturing is also easier, and up-close visualisation of difficult-to-reach areas may also help. Drawbacks of rRPLND include an overall smaller field of exposure than in open surgery and the risk of off-screen injury to structures such as viscera or major vessels.

During development of the rRPLND programme in our institution, we began with a lateral approach, but have subsequently moved to a supine technique in the Trendelenberg position. We find that a supine position allows broader access to the great vessels and facilitates easier dissection and suturing in a horizontal position. Maintaining a broad approach to the vessels is a key principle in avoiding and safely controlling bleeding. Surgeons should obtain as much exposure as possible before tackling difficult or high-risk areas, particularly when the tumour is adherent

to the great vessels. Getting above and below the area of interest before excision of the mass is the safest approach.

If there is any significant bleeding, the operating surgeon should confirm with the assistant and scrub team that rescue sutures are available and ask for full concentration and readiness. For venous bleeding, pneumoperitoneum should be quickly increased to 18–20 mm Hg. Pressure should be applied to the bleeding site with the fourth arm or the assistant suction device. A tonsil or similar swab can be introduced to allow the application of broader pressure.

There should be a firm but calm announcement to the theatre team and anaesthetist to explain that there is a significant vascular issue and blood may be sent for. Surgeons must have a range of techniques at their disposal to allow them to tackle bleeding from different sources.

We recommend use of a 4-0 PROLENE rescue stitch (Table 2) for most vascular bleeding events, while 5-0 PROLENE is preferred for caval injury. After each bite, the suture can be elevated in the nondominant instrument hand to maintain some anterior pressure. If bleeding is more significant, a suture with a Hem-o-Lok clip on the end can be used to elevate and occlude the vascular opening temporarily while further control and aspiration are performed. If this fails, clamps can be utilised above and below the defect to facilitate safe repair. We routinely have a laparoscopic Satinsky clamp and Scanlan robotic bulldog clamps available. Depending on the skill level of the bedside assistant, a Satinsky clamp can provide rapid control of large defects. Robotic bulldog clamps may be preferable as the console surgeon can control placement, but additional time is needed to introduce them into the field.

Venous bleeding is generally best controlled via suturing. Diathermy may not work and can result in enlargement of the venous defect. Bleeding lumbar veins can be particularly challenging to manage as they are short and may retract in a way that means it is often not possible to lift them up for control with a clip. If there is anticipated venous bleeding, then it may be sensible to place a sling around the cava ahead of time, so that if bleeding occurs this can be used to gain control while the defect is dealt with. If venous bleeding is from a very small tributary of the IVC, a clip may be applied beneath the opening. Clips can be applied by an experienced assistant; for challenging angles, a robotic clip applier may be preferable. If the vein is short, it is wise to oversew the clip to ensure that it is secure. Suturing in a cruciate or figure-of-eight formation will often allow better closure of the defect and prevent sutures tearing out; each throw should be made in a smooth motion to prevent further tearing of the delicate venous tissues.

Robotic vessels sealers can be helpful in controlling bleeding from veins or arteries but do require upward traction on the vessel to allow adequate space for the jaws of the sealer; this is not always possible.

Small arteries are more amenable to control with diathermy than veins. For anything larger, the use of clips or suturing is advised. Robotic repair of an aortic injury during rRPLND has been described by one group [10], whereas an aortic injury necessitated open repair in another report [12].

After surgical control of bleeding is achieved, and at the end of the procedure (to check for unrecognised bleeding), a



low-pressure haemostasis check should be performed and a haemostatic product such as Evicel can be applied. A Robison drain is left in place on completion of the procedure.

Should conversion to an open approach be required for any reason, the surgeon must be realistic about the amount of time required to make this transition. If the reason for conversion is significant bleeding, the goal must be to obtain adequate or partial control of the situation before conversion. Conversion before obtaining at least temporary control (eg, with compression or grasping of the bleeding point with an instrument) may lead to life-threatening blood loss.

In this paper we have focused primarily on key sites of retroperitoneal bleeding risk specific to rRPLND. Surgeons must also recognise that complications may occur during abdominal entry and exit. Care should be taken to avoid injuring any vessels during port placement, and all ports should be removed under vision to ensure that potential port-site bleeding does not go unnoticed at the end of the case. Vascular injury can occur during bowel mobilisation when gaining exposure to the great vessels. One group described an inferior mesenteric artery injury during rRPLND that was repaired robotically [13].

#### 4.2.2. Nontechnical factors

Nontechnical factors play a large part in both the prevention of and response to intraoperative complications.

Teamwork failures strongly correlate with the occurrence of technical errors. A study of cardiac surgical cases compared the effectiveness of two different teams in the operating theatre, one familiar with and the other unfamiliar with the operating surgeon and the procedure being performed. The primary team had better communication and fewer errors [14]. This highlights the importance of considering operating room team composition and ensuring a consistent team for high-risk procedures. In addressing bleeding, it may also be necessary to call on a wider team for support. Collaboration with vascular surgeons is valuable, particularly if patch grafting or aortic injury repair is required.

Effective teamwork relies on communication. Communication errors have a high risk of leading to a complication. In one study, as many as 36% of communication errors resulted in an adverse event [15]. In another study, 43% of errors made during surgery were attributed to incomplete or erroneous communication [16]. Surgeons and other team members all need to be able to communicate calmly and clearly and with authority the issues and any instructions to the team. Repetition of instructions back to the surgeon before action ensures clear comprehension of the request.

Checklists and briefings have been proposed as tools to improve safety and process reliability. While they can be effective in reducing system failures, they can only do so if they are well designed and used appropriately [17]. The World Health Organization checklist is now a routine part of all surgical procedures. These principles can be adapted to a more case-specific checklist that aids in team preparation during briefing. A relevant and clear team briefing

before the case can set the scene for effective communication throughout.

A key skill for all surgeons is decision-making. If something unexpected happens during an operation, the surgeon must be able to think quickly and act with precision. It is important that there is no shouting or excessive rushing. Panic can lead to greater error, on the part of both the surgeon and the team. A measured response, although difficult, is required at all times.

## 5. Conclusions

Significant bleeding during rRPLND, although rare, does occur and may have major consequences for the patient. Attention to appropriate case selection, knowledge of anatomic vascular variations, advanced robotic dissection and suturing skills, and intraoperative teamwork help in minimising the risk of intraoperative haemorrhage. rRPLND is generally a very safe and feasible technique in well-selected cases and has large potential patient benefits. The procedure requires a highly experienced robotic team that can adapt to situations rapidly and work well under pressure.

**Conflicts of interest:** The authors have nothing to disclose.

## References

- [1] Mittakanti HR, Porter JR. Robot-assisted laparoscopic retroperitoneal lymph node dissection: a minimally invasive surgical approach for testicular cancer. *Transl Androl Urol* 2020;9: S66–73.
- [2] Schwen ZR, Gupta M, Pierorazio PM. A review of outcomes and technique for the robotic-assisted laparoscopic retroperitoneal lymph node dissection for testicular cancer. *Adv Urol* 2018;2018:2146080.
- [3] Stephenson A, Eggener SE, Bass EB, et al. Diagnosis and treatment of early stage testicular cancer: AUA guideline. *J Urol* 2019;202:272–81.
- [4] Calaway AC, Einhorn LH, Masterson TA, Foster RS, Cary C. Adverse surgical outcomes associated with robotic retroperitoneal lymph node dissection among patients with testicular cancer. *Eur Urol* 2019;76:607–9.
- [5] Brennan TA, Leape LL, Laird NM, et al. Incidence of adverse events and negligence in hospitalized patients. Results of the Harvard Medical Practice Study I. *N Engl J Med* 1991;324:370–6.
- [6] Gawande AA, Thomas EJ, Zinner MJ, Brennan TA. The incidence and nature of surgical adverse events in Colorado and Utah in 1992. *Surgery* 1999;126:66–75.
- [7] Hillelsohn JH, Duty BD, Okhunov Z, Kavoussi LR. Laparoscopic retroperitoneal lymph node dissection for testicular cancer. *Arab J Urol* 2012;10:66–73.
- [8] Baniel J, Foster RS, Donohue JP. Surgical anatomy of the lumbar vessels: implications for retroperitoneal surgery. *J Urol* 1995;153:1422–5.
- [9] Beveridge TS, Allman BL, Johnson M, Power A, Sheinfeld J, Power NE. Retroperitoneal lymph node dissection: anatomical and technical considerations from a cadaveric study. *J Urol* 2016;196: 1764–71.
- [10] Singh A, Chatterjee S, Bansal P, Bansal A, Rawal S. Robot-assisted retroperitoneal lymph node dissection: feasibility and outcome in postchemotherapy residual mass in testicular cancer. *Indian J Urol* 2017;33:304–9.
- [11] Fernando A, Reeves F, Oluwole-Ojo A, et al. Robot-assisted retroperitoneal lymph node dissection for testis cancer: moving from feasible to mainstream. *J Clin Urol* 2022;15(1 Suppl):P3–6.

- 
- [12] Pearce SM, Golan S, Gorin MA, et al. Safety and early oncologic effectiveness of primary robotic retroperitoneal lymph node dissection for nonseminomatous germ cell testicular cancer. *Eur Urol* 2017;71:476–82.
- [13] Grenabo Bergdahl A, Månsson M, Holmberg G, Fovaeus M. Robotic retroperitoneal lymph node dissection for testicular cancer at a national referral centre. *BJUI Compass* 2022;3:363–70.
- [14] ElBardissi AW, Wiegmann DA, Henrickson S, Wadhera R, Sundt 3rd TM. Identifying methods to improve heart surgery: an operative approach and strategy for implementation on an organizational level. *Eur J Cardiothorac Surg* 2008;34:1027–33.
- [15] Lingard L, Regehr G, Orser B, et al. Evaluation of a preoperative checklist and team briefing among surgeons, nurses, and anesthesiologists to reduce failures in communication. *Arch Surg* 2008;143:12–7.
- [16] Gawande AA, Zinner MJ, Studdert DM, Brennan TA. Analysis of errors reported by surgeons at three teaching hospitals. *Surgery* 2003;133:614–21.
- [17] Shouhed D, Gewertz B, Wiegmann D, Catchpole K. Integrating human factors research and surgery: a review. *Arch Surg* 2012;147:1141–6.