

Brief Correspondence

Confirmation by Early Oncologic Outcomes After Surgery of the Accuracy of Intermediate-risk Prostate Cancer Classification Based on Magnetic Resonance Imaging Staging and Targeted Biopsy

Cécile Manceau^{a,*}, Jean-Baptiste Beauval^b, Marine Lesourd^a, Christophe Almeras^b, Jean-Romain Gautier^b, Michel Soulié^a, Guillaume Loison^b, Ambroise Salin^b, Christophe Tollon^b, Bernard Malavaud^a, Mathieu Roumiguié^a, Guillaume Ploussard^b

It has been demonstrated that magnetic resonance imaging (MRI) is a valuable tool in improving the diagnosis of clinically significant prostate cancer (PCa) [1]. MRI-targeted biopsy (TB) improves PCa diagnosis by increasing the detection of significant PCa and decreasing the detection of insignificant PCa [2]. Localised PCa is a heterogeneous entity with different prognoses. The goal is to differentiate patients with poor prognosis from those with good prognosis to reinforce therapy in aggressive cases and to avoid unnecessary treatments in favourable ones. Efforts are being made to update the current predictive tools by incorporating MRI data and TB pathology findings [3].

The classification proposed by d'Amico et al [4] based on digital rectal examination (DRE), Gleason score and prostate-specific antigen (PSA) stratifies men into low-, intermediate-, and high-risk groups. However, intermediate-risk cases are a heterogeneous group, leading to subclassification between favourable and unfavourable cases. This validated intermediate risk classification (IRC) was introduced by Zumsteg et al [5] and is described in the National Comprehensive Cancer Network guidelines, with unfavourable disease defined as patients who have at least one of the following criteria: two or more intermediate risk factors, grade group (GG) ≥ 3 , or more than half of biopsy cores showing cancer. Nevertheless, MRI and TB features are not taken into account, which could lead to inaccurate assessment for patients with positive MRI findings.

Roumiguié et al [6] recently used MRI criteria and TB data to improve this IRC. The favourable group was defined as men with the absence of extracapsular extension (ECE) on MRI and GG < 3 on TB; all other cases (any ECE on MRI and/or GG ≥ 3 on TB) were classified as unfavourable intermediate-risk

disease. This new IRC significantly improved the prediction of final pathology and could reduce the risk of overtreatment for misclassified unfavourable intermediate-risk cases. The aim of our study was to validate the accuracy of this new IRC with early oncologic outcomes and biochemical recurrence (BCR) after RP.

We selected from our prospective database consecutive patients between January 2014 and July 2019 with intermediate-risk PCa who had positive prebiopsy mpMRI findings (Prostate Imaging-Reporting and Data System score ≥ 3) followed by systematic biopsy (SB) in combination with TB. SBs were performed randomly, and the number of targeted cores taken for each suspicious lesion on mpMRI was chosen at the physician's discretion, with a median of four TBs per lesion. Overall, 454 patients with intermediate-risk PCa were included who had one or more intermediate risk factors (PSA 10–20 ng/mL, GG 2–3, stage T2b/T2c on DRE) and no high risk factor (GG 4–5, PSA > 2 ng/mL, or stage $\geq T3$ on DRE). Biochemical follow-up was standardised with a PSA test at 6 wk, 3 mo, 6 mo, and then every 6 mo after surgery. No patient received any neoadjuvant or adjuvant treatment without BCR.

BCR was defined as any confirmed PSA value > 0.2 ng/mL. The median follow-up was 31.5 mo. Overall, 7.9% of patients experienced BCR. The patient characteristics and pathology results are presented in Supplementary Table 1. The mean patient age was 64.7 yr. Mean PSA was 8.4 ng/mL (median 8) and mean PSA density was 0.19 ng/mL/g (median 0.18). ECE on MRI was reported for 11.7% of the patients and GG ≥ 3 on TB for 22.4%. ECE on MRI was confirmed on radical prostatectomy for 61.1%. Baseline characteristics and pathology outcomes for the favourable and unfavourable

Table 1 – Baseline characteristics and pathology outcomes for the favourable and unfavourable subgroups according to the standard IRC and new IRC.

	Standard IRC			New IRC		
	Favourable	Unfavourable	<i>p</i> value	Favourable	Unfavourable	<i>p</i> value
Patients (%)	35.9	64.1		70.3	29.7	
Clinical stage (%)	0.6	0.7	<0.001	0.6	0.8	0.46
T1b	93.2	51.9		68.5	62.4	
T1c	6.2	47.4		30.9	36.8	
T2						
PI-RADS score (%)	36.2	14.1	<0.001	28.5	6.7	<0.001
PIRADS 3	47.9	52.6		52.0	48.1	
PIRADS 4	16.0	33.3		19.4	45.2	
PIRADS 5						
3-T MRI (%)	4.9	15.5	0.001	0.0	34.1	<0.001
Biopsy GG for TB+SB (%)	34.4	3.1	<0.001	20.4	0.0	<0.001
1	65.6	58.1		75.5	25.9	
2	0.0	38.8		4.1	74.1	
3						
Biopsy GG on TB (%)	19.0	8.9	<0.001	17.9	0.0	<0.001
0	25.8	7.6		20.1	0.0	
1	54.6	48.8		62.1	24.4	
2	0.6	34.0		0.0	74.1	
3	0.0	0.7		0.0	1.5	
4						
Biopsy GG on SB (%)	17.8	10.3	<0.001	13.8	11.1	<0.001
0	45.4	21.6		34.8	19.3	
1	36.8	51.5		47.6	43.0	
2	0.0	16.2		3.4	26.7	
3	0.0	0.3		0.3	0.0	
4						
pT stage (%)	62.6	45.4	0.001	58.3	35.6	<0.001
pT2	29.4	39.9		32.9	43.7	
pT3a	8.0	14.8		8.8	20.7	
pT3b–4						
pN stage (%)	71.2	84.9	<0.001	77.7	85.2	0.001
pN0	1.2	6.2		1.6	11.1	
pN1	27.6	8.9		20.7	3.7	
pNx						
GG on RP (%)	6.7	2.7	<0.001	5.3	1.5	<0.001
1	71.2	52.2		69.0	35.6	
2	20.2	41.6		23.5	58.5	
3	1.2	1.0		0.9	1.5	
4	0.6	2.4		1.3	3.0	
5						
Positive margin (%)	19.0	18.2	0.9	16.9	22.2	0.18
Biochemical recurrence (%)	4.9	9.8	0.102	5.7	13.7	0.007

GG = grade group; IRC = intermediate risk classification; MRI = magnetic resonance imaging; PI-RADS = Prostate Imaging-Reporting and Data System; RP = radical prostatectomy; SB = systematic biopsy; TB = targeted biopsy.

subgroups according to the standard IRC and new IRC are presented in Table 1. The standard IRC classed 35.9% of patients in the favourable group and 64.1% in the unfavourable group, whereas the corresponding proportions according to the new IRC were 70.1% and 29.1%. Some 48.8% of patients in the unfavourable group according to the standard IRC were misclassified and had favourable intermediate-risk disease (without ECE or lymph node invasion and with GG ≤ 2), whereas only 32.6% were misclassified according to the new IRC.

Using the new IRC, 5.7% of men in the favourable subgroup and 13.7% in the unfavourable subgroup had BCR, while the corresponding rates using the standard IRC were 4.9% and 9.7%.

Survival curves assessed using the Kaplan-Meier method and the log-rank test showed a significant difference

($p = 0.004$) between the favourable and unfavourable groups according to the new IRC (Fig. 1). The area under the receiver operating characteristic curve was 0.613 for the new IRC versus 0.575 for the standard IRC (Supplementary Fig. 1). Importantly, the new IRC reclassified half of unfavourable cases in the standard IRC as favourable intermediate-risk disease, and these reclassified patients could avoid unnecessary aggressive treatment.

mpMRI with TB improves the accuracy of models based on clinical data in predicting adverse pathology and should be incorporated into routine practice and novel models [7,8]. Our study revealed that a predictive model that includes ECE on MRI and TB improved BCR prediction, in addition to final pathology prediction, in comparison to the standard IRC. In this population of patients, BCR has been linked to more advanced disease

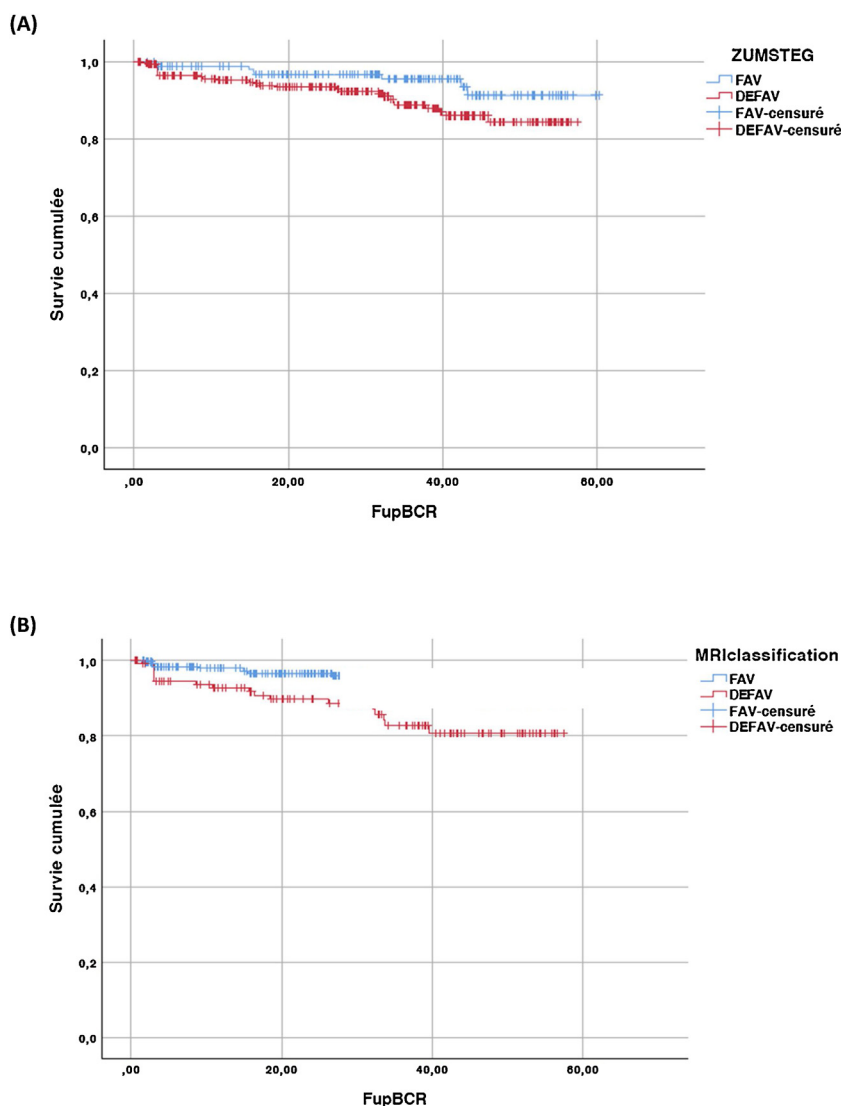


Fig. 1 – Kaplan-Meier estimate of biochemical recurrence (BCR)-free survival in favourable and unfavourable subgroups according to (A) the standard (log rank $p = 0.049$) and (B) the new (log rank $p = 0.004$) intermediate risk classification.

and higher rates of metastasis and prostate cancer-specific mortality [9].

Our study confirms that standard IRC is not optimal and that new tools such as mpMRI and TB should be used to improve the evaluation of intermediate-risk PCa. The new IRC could be improved but remains an easy-to-use model and allows for reclassification of 56% of unfavourable cases misclassified in the standard IRC (Supplementary Table 2). This represents a clinically relevant improvement, especially in reducing overtreatment. The rate of BCR in intermediate-risk PCa remains low at only 7.9% in our study, so a larger prospective study is needed to confirm our findings.

In the heterogeneous population of men with MRI-positive intermediate-risk PCa, the addition of MRI and TB features to the IRC significantly improved the prediction of final pathology and of early oncologic outcomes after RP. The use of this new IRC can optimise treatment decision-making by providing more accurate discrimina-

tion of favourable and unfavourable risk groups. This could result in a decrease in overtreatment (neoadjuvant therapy or long-term androgen deprivation associated with radiation).

Author contributions: Cécile Manceau had full access to all the data in the study and takes responsibility for the integrity of the data and the accuracy of the data analysis.

Study concept and design: Ploussard, Manceau, Malavaud, Roumiguié.

Acquisition of data: Ploussard, Manceau, Beauval, Lesourd, Almeras, Gautier, Loison, Salin, Soulié, Tollon, Malavaud, Roumiguié.

Analysis and interpretation of data: Ploussard, Manceau.

Drafting of the manuscript: Ploussard, Manceau.

Critical revision of the manuscript for important intellectual content: Ploussard, Manceau.

Statistical analysis: Ploussard, Manceau.

Obtaining funding: None.

Administrative, technical, or material support: Ploussard, Manceau.

Supervision: Ploussard.

Other: None.

Financial disclosures: Cécile Manceau certifies that all conflicts of interest, including specific financial interests and relationships and affiliations relevant to the subject matter or materials discussed in the manuscript (eg, employment/affiliation, grants or funding, consultancies, honoraria, stock ownership or options, expert testimony, royalties, or patents filed, received, or pending), are the following: None.

Funding/Support and role of the sponsor: None.

Appendix A. Supplementary data

Supplementary material related to this article can be found, in the online version, at doi:<https://doi.org/10.1016/j.euros.2020.07.003>.

References

- [1] Le JD, Tan N, Shkolyar E, et al. Multifocality and prostate cancer detection by multiparametric magnetic resonance imaging: correlation with whole-mount histopathology. *Eur Urol* 2015;67:569–76.
- [2] Rouvière O, Puech P, Renard-Penna R, et al. Use of prostate systematic and targeted biopsy on the basis of multiparametric MRI in biopsy-naïve patients (MRI-FIRST): a prospective, multicentre, paired diagnostic study. *Lancet Oncol* 2019;20:100–9.
- [3] Ploussard G, Beauval JB, Lesourd M, et al. Added value of concomitant systematic biopsies for grade group prediction based on radical prostatectomy final pathology in MRI-positive patients undergoing fusion targeted biopsies. *J Urol* 2019;202:1182–7.
- [4] D'Amico AV, Whittington R, Malkowicz SB, et al. Biochemical outcome after radical prostatectomy, external beam radiation therapy, or interstitial radiation therapy for clinically localized prostate cancer. *JAMA* 1998;280:969–74.
- [5] Zumsteg ZS, Spratt DE, Pei I, et al. A new risk classification system for therapeutic decision making with intermediate-risk prostate cancer patients undergoing dose-escalated external-beam radiation therapy. *Eur Urol* 2013;64:895–902.
- [6] Roumiguie M, Lesourd M, Zgheib J, et al. Improvement of the intermediate risk prostate cancer sub-classification by integrating MRI and fusion biopsy features. *Urol Oncol* 2020;38:386–92.
- [7] Feng TS, Sharif-Afshar AR, Wu J, et al. Multiparametric MRI improves accuracy of clinical nomograms for predicting extracapsular extension of prostate cancer. *Urology* 2015;86:332–7.
- [8] Gandaglia G, Ploussard G, Valerio M, et al. The key combined value of multiparametric magnetic resonance imaging, and magnetic resonance imaging-targeted and concomitant systematic biopsies for the prediction of adverse pathological features in prostate cancer patients undergoing radical prostatectomy. *Eur Urol* 2020;77:733–41.
- [9] Van den Broeck T, van den Bergh RCN, Arfi N, et al. Prognostic value of biochemical recurrence following treatment with curative intent for prostate cancer: a systematic review. *Eur Urol* 2019;75:967–87.

^aDepartment of Urology, CHU-IUC, Toulouse, France

^bDepartment of Urology, La Croix du Sud Hospital, Quint Fonsegrives, France

*Corresponding author. Department of Urology, CHU Toulouse, Rangueil Hospital, Avenue Jean Poulhès, Toulouse, France. Tel. +33 5 61322285, Fax: +33 5 61323229.

E-mail address: cecile.manceau2@gmail.com (C. Manceau).