

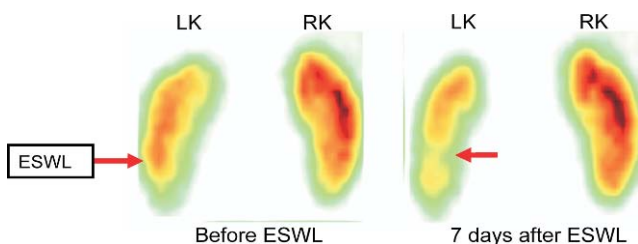
**N105****Evaluation of renal function following extracorporeal shock wave lithotripsy (ESWL): The use of parametric clearance kidney scintigrams**

T. Konecki<sup>1</sup>\*, I. Frieske<sup>2</sup>, J. Kusmierk<sup>2</sup>, M. Sosnowski<sup>1</sup>. <sup>1</sup>Medical University, Dept. of Urology, Lodz, Poland; <sup>2</sup>Medical University, Dept. of Nuclear Medicine, Lodz, Poland

**Introduction and Objectives:** Extracorporeal shock wave lithotripsy (ESWL) has gained a widespread acceptance due to its effectiveness and noninvasiveness. However, the safety of ESWL has been debated in recent years. Reports of renal parenchymal damage in treated kidneys in animal model suggest local contusions occurring in a remarkable number of treated kidneys. The aim of the prospective study was to evaluate the effect of ESWL on renal function using parametric clearance kidney scintigrams.

**Material and Methods:** A total of 41 patients with untreated, single renal stone the size of 10–20 mm and no hydronephrosis on ultrasound and intravenous pyelography were evaluated before, 7 days after and one month after ESWL with renoscintigraphy. To assess the effect of ESWL on renal function, 99mTc-EC parametric clearance image findings and differential renal function parameters at presentation and followup were reviewed. Parametric clearance kidney imaging is a method of functional imaging of the kidney clearance that was elaborated in Nuclear Medicine Department of Medical University in Lodz, based on the Patlak-Rutland theory. The intensity of a colour in such obtained images is proportional to the local clearance value.

**Results:** See the figure. Analysis of parametric clearance kidney images revealed local parenchymal defects in 16 patients (39%) 7 days after ESWL. These changes resolved in 14 (34%) cases at one month follow-up. The other two patients had an additional renoscintigraphy performed three months after ESWL that showed no disturbances in the distribution of renal clearance in the treated kidney. There were no statistically significant differences observed between renoscintigraphic parameters describing the function of the whole organ before and after ESWL. The figure shows parametric renal clearance images obtained before and 7 days after ESWL of a calculus located in the lower calyx of left kidney.



**Conclusions:** Extracorporeal shock wave lithotripsy may cause a transient reduction of regional function of the treated kidney.

**N106****Nephrostomy in pregnancy**

L. Wojnar\*, A. Antczak, Z. Kwias. University of Medicine, Dept. of Urology, Poznań, Poland

**Introduction and Objectives:** Nephrostomy is a fast and safe way to relief pain and unblock the renal collecting system in pregnancy. Nephrostomy should be performed under ultrasonography by qualified doctor. Nephrostomy is a minimally invasive treatment of hydronephrosis during pregnancy. It is safe for a woman and fetus.

**Material and Methods:** The study was made on the group of 9 pregnant patients, between 20th and 35th week of pregnancy.

The study was made during two years time, among the young women, age between 24 to 30 years old. Nephrostomy was performed in all patient on the right side (100%), in one case intervention failed (11%) – instead the D-J catheter was placed into the ureter.

**Results:** All patients, who had successfully performed percutaneous nephrostomy, immediately felt better, relieved pain and fever, pharmacological treatment was stopped. 7 patients (77%) suffered from hydronephrosis because of physiological syndroms in pregnancy and 2 patients suffered from ureterolithiasis during pregnancy (22%).

**Conclusions:** Percutaneous nephrostomy was performed under ultrasonography by skilled doctor, who minimized the side effects of this treatment. It is a very good way to unblock the renal collecting system, which relief the symptoms of infection and pain, also postpone further treatment of ureterolithiasis after parturition.

**N107****Hair stem cells for bladder regeneration in rats, preliminary results**

T. Drewna<sup>1</sup>\*, R. Joachimiak<sup>2</sup>, A. Kaznica<sup>2</sup>, V. Sarafian<sup>3</sup>, M. Pokrywczynska<sup>2</sup>. <sup>1</sup>Nicolaus Copernicus University, Dept. of Urology, Bydgoszcz, Poland; <sup>2</sup>Nicolaus Copernicus University, Dept. of Biology, Bydgoszcz, Poland; <sup>3</sup>Plovdiv University, Dept. of Biology, Plovdiv, Bulgaria

**Introduction and Objectives:** A variety of tissue engineering techniques for bladder augmentation are currently under development or investigation, but thus far, no one approach is clearly superior. The aim of the study is to compare the suitability for cystoplasty augmentation in rats of in vivo implanted bladder acellular matrices previously seeded with hair follicle stem cells and of matrices implanted without cells (BAM, bladder acellular matrix).

**Material and Methods:** The rat hair follicle stem cell line was used. Cells were positive for CD34, p63 and Ki-67. 1×10<sup>6</sup> cells from 34–40 passages were seeded on 9 BAM scaffolds and cultured for a week. Nine scaffolds were left unseeded. Scaffolds were grafted into a surgically created defect within the anterior bladder wall. 9 rats were grafted with acellular matrices and 9 with cell seeded BAM. Rats were observed 6 months and sacrificed in monthly intervals. Gross examination, X-ray cystography, H&E, CK-7, CK-20, myoglobin and desmin staining of the excised bladders were performed.

**Results:** Minimal adhesions were observed. Urinary leakage was observed in one case. Two animals died in acellular group. Rats developed stone disease in bladders reconstructed with acellular BAM. Bladders' capacity was comparable but the shape was regular and characteristically oval only in bladders grafted with cell seeded BAM. Muscle layers in apical parts of the reconstructed bladder walls were extremely thin in the cases of acellular grafts and were thicker in bladders reconstructed with cell seeded grafts. Muscle layer regeneration was better in the cell-seeded group. Urothelium regenerated in all animals.

**Conclusions:** We present for the first time that hair follicle stem cells can improve regeneration of the rat bladder wall. The differentiation of hair follicle stem cells has to be studied.